

# Rectal carcinoids are on the rise: early detection by screening endoscopy

## Author

H. Scherübl

## Institution

Klinik für Innere Medizin, Gastroenterologie und Gastrointestinale Onkologie, Klinikum Am Urban, Vivantes Netzwerk für Gesundheit, Berlin, Germany

## Bibliography

DOI 10.1055/s-0028-1119456  
Endoscopy 2009; 41:  
162–165 © Georg Thieme  
Verlag KG Stuttgart · New York  
ISSN 0013-726X

## Corresponding author

**H. Scherübl, MD, PhD**  
Klinik für Innere Medizin  
Gastroenterologie und Gastro-  
intestinale Onkologie  
Vivantes-Klinikum Am Urban  
Dieffenbachstrasse 1  
10967 Berlin  
Germany  
Fax: +49-30-130225205  
hans.scheruebl@vivantes.de

Rectal carcinoids are on the rise; in the United States the age-adjusted incidence has increased by 800%–1000% in the last 35 years. The incidence of carcinoids of the stomach, pancreas, or small bowels has also multiplied. The reasons for these epidemiological changes are not yet understood. Both screening sigmoidoscopy and screening colonoscopy lead to a shift to smaller-sized ( $\leq 13$  mm) rectal carcinoids and earlier tumor stages at diagnosis. During the last 35 years the overall 5-year survival of patients with rectal carcinoid disease has increased by almost 20% (in the US). Thus, endoscopic screening of the colo-

rectum is effective in the early diagnosis not only of colorectal adenomas and adenocarcinomas but also of carcinoids. Rectal carcinoids that are 10.0 mm or less and do not infiltrate the muscularis propria can be removed endoscopically. If histological angioinvasion or lymph node metastases are found, surgical lymph node dissection has to be considered. Before deciding on definitive therapy, rectal carcinoids should be staged by means of endoscopic ultrasonography, CT, or MRI and somatostatin receptor scintigraphy.

## Background

Colorectal cancer (colorectal adenocarcinoma) is largely preventable with regular screening and is treatable if detected early. Thanks to screening, the death rate from colorectal cancer is steadily declining in (Western) countries with established screening facilities.

Although adenocarcinoma is the most prevalent colorectal neoplasm, it is not the only one. The age-adjusted incidence of well-differentiated neuroendocrine tumors and cancers of the colorectum (colorectal carcinoids) is about 1 in 100 000 [1]. The Surveillance, Epidemiology, and End Results (SEER) registry database of the National Cancer Institute (which reflects the standard of care for the average US citizen) shows that the age-adjusted incidence of rectal carcinoids has increased about tenfold over the last 35 years [1,2]. In the United States, 50% or more of rectal carcinoids are nowadays diagnosed as “incidentally” identified lesions, due to the increased availability and use of screening sigmoidoscopy and/or colonoscopy [2]. The prevalence of rectal carcinoids in adults undergoing screening endoscopy (mean/median age: 48.8–54 years) is known to be 0.05%–0.07% [3,4].

In 2006, 57.1% of US men and women aged 50 years or older reported they had undergone at least one examination with flexible sigmoidoscopy or colonoscopy [5]. Since about 55 000 000 US citizens have been “scoped,” on the basis of a prevalence rate of 0.05%–0.07% one would expect some 27 500–38 500 rectal carcinoids to have been diagnosed “incidentally” by screening endoscopy in the United States. This is the reason why rectal carcinoids have recently attracted our attention.

Due to a lack of controlled prospective studies, the management of rectal carcinoids is a matter of debate. In this report the retrospective data from large national registries and large hospital series are reviewed.

As concerns nomenclature, (well-differentiated) neuroendocrine neoplasms of the rectum that either show angioinvasion or infiltration of the muscularis propria (or beyond) or have metastasized are called neuroendocrine carcinomas. The term “rectal carcinoid” does not distinguish between well-differentiated neuroendocrine carcinoma and well-differentiated neuroendocrine tumor (of the rectum); it comprises both [6].

## Prognosis of rectal carcinoids

The risk of lymph node metastasis of rectal carcinoids is no smaller than the metastatic risk of rectal adenocarcinoma [6–10]. Importantly, the prognosis of patients with metastatic rectal carcinoid disease is no better than the prognosis of patients suffering from metastatic rectal adenocarcinoma [2, 7–11].

The 5-year survival of patients with rectal carcinoid disease who have distant metastases is 15%–30% [2, 6, 7–9]. For node-positive rectal carcinoid disease (without distant metastases at the time of diagnosis), 5-year survival is 54%–73% [2, 7–9]. In contrast to this, histologically node-negative rectal carcinoids that are smaller than 1 cm and do not show angioinvasion or infiltration of the muscularis propria are associated with an excellent 5-year survival of 98.9%–100% [1, 2, 6–9].

## Endoscopic screening to detect early rectal carcinoids

In large national or hospital series such as the SEER database, the Japanese Multi-Institutional Registry of Large-Bowel Cancer and the Japanese Niigata database, about 10%–15% of rectal carcinoids were found to measure more than 2 cm in size and 10%–22% of rectal carcinoids were 11–20 mm in diameter at the time of diagnosis [2, 6–9, 12]. In contrast, rectal carcinoids detected by screening endoscopy are no more than 13 mm in diameter; 39 out of 40 carcinoids (97.5%) measured less than 10.1 mm in diameter [3, 4] (Table 1).

Kaminski et al. [3] analyzed 50 148 screening colonoscopies from the colorectal cancer screening program in Poland. They recorded 25 rectal carcinoids in 24 patients (median age: 54 years). The maximum size of the 25 carcinoids was 10.0 mm (median: 6 mm). Two of the 25 rectal carcinoids (8%) were neuroendocrine carcinomas (J. Regula and M. Kaminski, personal communication). Similar prevalence rates were reported from Japan and Korea. In 21 522 Japanese teachers (mean age: 48.8 years), Matsui et al. [4] detected 15 rectal carcinoids by screening sigmoidoscopy. The maximum size of the carcinoids did not exceed 13 mm (mean diameter: 6 mm). A similar prevalence rate of rectal carcinoids (0.08%) was reported in 86 918 Korean patients who underwent endoscopy [13]. Thus, screening endoscopy is highly effective in the early diagnosis of rectal carcinoids; it leads to a shift to smaller-sized rectal carcinoids and to more favorable (earlier) tumor stages at diagnosis [3, 4].

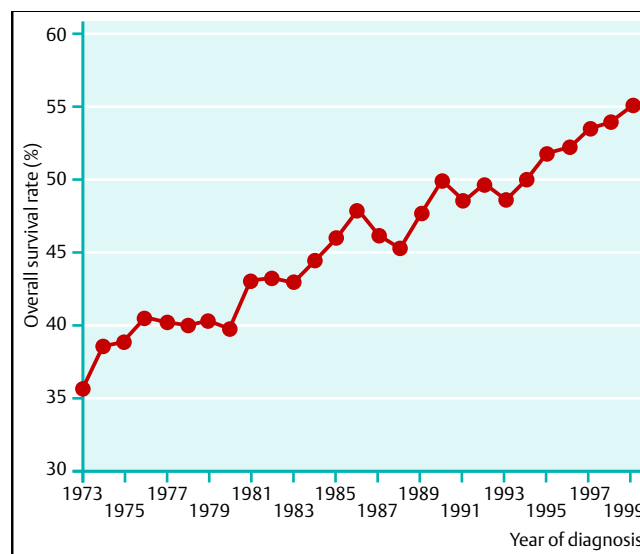
This is in line with the steadily improving overall 5-year survival observed by Modlin and coworkers [2] (Fig. 1) in rectal carcinoid patients when they analyzed the SEER database records for the last 35 years. Hence, screening sigmoidoscopy and colonoscopy are highly effective not only in the early detection of colorectal adenomas and adenocarcinomas but also in the early detection of neuroendocrine neoplasms of the (colo-)rectum.

## Treatment of rectal carcinoids

When deciding on the management of rectal carcinoids, the disease stage should be taken into account. Best palliative therapy is required for advanced tumor disease. Lymph node dissection has to be considered for node-positive carcinoid disease in a fit patient. Local treatment of any rectal carcinoid smaller than 2 cm is a matter of debate. [17, 25]. Particularly in elderly or mul-

**Table 1** Efficacy of endoscopic screening for rectal carcinoids. The risk of metastatic spread is 3%–9.8% in rectal carcinoids smaller than 10.0 mm, amounts to 17%–81% in rectal carcinoids 10.1–20 mm in size, and rises to 60%–80% when the tumor exceeds 20 mm in diameter [2, 6–11, 15, 16]. Screening endoscopy leads to detection of rectal carcinoids of smaller size and earlier stage [3, 4].

Size of the primary tumor	Without screening, %	With endoscopic screening, %
≤ 10 mm	65–80	93.3–100
11–20 mm	10–22	0–6.7
> 20 mm	10–15	0



**Fig. 1** Survival of patients with rectal carcinoid disease. Overall 5-year survival rates were calculated for rectal carcinoid patients in the SEER database. A significant increase in survival is observed between 1973 and 1999 (modified from [2]).

timorbid patients it is very important to balance the relative risks and benefits of conservative versus surgical management; often a less aggressive treatment strategy should be chosen in such situations. In relation to treatment, at least in Western countries, rectal carcinoids used to be classified into tumors larger than 2 cm, tumors 10.1–20 mm in size, and tumors 10.0 mm or less in diameter.

## Rectal carcinoids larger than 2 cm

Even today some patients present with rectal carcinoids that are over 2 cm in size. According to the SEER database, 60%–80% of rectal carcinoids that are larger than 2 cm metastasize [2, 12]. For this reason, most clinicians in the United States, Japan, and Europe agree that localized rectal carcinoids larger than 2 cm should be managed surgically including with lymph node dissection [2, 6–9, 11, 13–15]. Ulcerated colorectal carcinoids should be treated along the same lines. In a Korean series of 67 rectal carcinoids [13], three out of four ulcerated rectal carcinoids were found to have spread.

## Rectal carcinoids smaller than 2 cm

A great body of evidence shows that rectal carcinoids that are 1 cm or less in size metastasize in 3%–9.8% of cases [1–3, 6–9, 11, 12, 16, 17], whereas rectal carcinoids that are 10.1–20 mm

in diameter spread to regional lymph nodes in 17%–81% of patients [1–3,6–12,15–17]. Lymph node dissection has to be considered in patients with node-positive carcinoid disease [6–11,16,18].

As for optimal staging of localized rectal adenocarcinoma, we nowadays advise patients to undergo pelvic magnetic resonance imaging (MRI) and endoscopic ultrasonography (in nonstenotic cancer). Unlike the standard of care in rectal adenocarcinoma, traditionally our practice was to use endoscopic ultrasonography and/or pelvic MRI in only a few patients with rectal carcinoid disease [16]. In light of the risk of metastases, however, nowadays we should stage all patients with carcinoids before deciding on treatment. Staging of (localized) rectal carcinoids should comprise endoscopic ultrasonography, pelvic MRI (or pelvic CT), a chest radiograph, a liver scan, and somatostatin receptor scintigraphy [19].

### Rectal carcinoids measuring 1 cm or less

A broad consensus exists regarding the management of small rectal carcinoids ( $\leq 10.0$  mm) that do not show lymphovascular invasion or infiltration of the muscularis propria or lymph node metastases. Such small, well-differentiated rectal carcinoids can be managed by local excision performed either endoscopically or surgically [2–5,7–9,15,17,18]. Before embarking on resection, the exact tumor size and in particular the depth of invasion has to be determined by endoscopic ultrasound. As 75% and more of rectal carcinoids infiltrate the submucosa, Sakata et al. [20] and Mashimo et al. [21] modified the ligation device for esophageal varices for use in the rectum, while Onozato et al. [22] went on to optimize endoscopic submucosal dissection. Applying these techniques, both groups achieved complete resection (R0) of small rectal carcinoids in 95.2%–100% of their patients [20–22]. When either endoscopic ultrasonography was omitted in tumor staging or conventional endoscopic techniques were used, indeterminate or even positive resection margins were observed on histological examination in as many as 31.8%–83% of patients [3,16,23]. When endoscopic ultrasonography was performed prior to endoscopic submucosal resection, the R1 rate dropped to 4.8%–17% [21,24]. Obviously, endoscopic ultrasonography should precede local therapy of rectal carcinoids. A thorough histological work-up of resected rectal carcinoids is important. As pointed out by Shinohara et al. [18] and by Kwaan et al. [16], well-differentiated rectal carcinoids exhibiting lymphovascular invasion or infiltration of the muscularis propria can have spread to regional lymph nodes even though the primary tumor measures less than 10 mm in diameter, and despite a normal appearance of the regional lymph nodes on imaging.

### Rectal carcinoids measuring 1–2 cm

Local therapy of rectal carcinoids measuring 10.1–20 mm in diameter is a matter of debate [11,17,25]. There are no controlled prospective studies on this issue. Local excision of any rectal carcinoid smaller than 2 cm, as suggested by Ramage et al. [17], disregards the fact that 17%–81% of rectal carcinoids 10.1–20 mm in size metastasize to regional lymph nodes [7–9,11,16]. In Japan rectal carcinoids that are larger than 10.0 mm are treated surgically along the same lines as rectal adenocarcinomas [7–9,11]. There, lymph node dissection is considered the standard of care for rectal carcinoids 10.1–20.0 mm in size. Large Japanese registries [6–9] do report 5-year survival rates for patients with rectal carcinoids that are better than the 5-year survival rates reported from other parts of the world. When

comparing different treatment modalities for well-differentiated (neuro-)endocrine tumors, we have learned from diseases such as well-differentiated thyroid cancer that 10-year or even 15-year survival is a much more reliable and valid parameter than 5-year survival. Even patients who in the end die of their rectal carcinoid disease generally survive for the first 5 years [11,16]. For this reason, the 10-year survival rates of all patients suffering from neuroendocrine neoplasms of the rectum should be published for both the Japanese and the SEER registries. In addition, 10-year survival rates from other databases should also be published.

### Advanced rectal carcinoid disease

Few patients with rectal carcinoids (<1%) develop a carcinoid syndrome. The carcinoid syndrome can be effectively controlled by medical therapy with either stable somatostatin analogues or interferon- $\alpha$ . Cytostatic therapy of advanced rectal carcinoid disease has not yet been evaluated in controlled prospective trials; neither have novel targeted therapies been studied in this setting [26]. The concept of adjuvant therapy after curative surgery of node-positive rectal carcinoids has not been addressed either.

### Conclusion



Endoscopic screening of the colorectum is effective in the early diagnosis not only of colorectal adenomas and adenocarcinomas but also of carcinoids. Coincident with the implementation of colorectal cancer screening, overall 5-year survival of patients with rectal carcinoid disease has steadily increased in the United States. For this reason, we should no longer regard rectal carcinoids detected by screening endoscopy as “incidentally identified lesions”. The early detection of colorectal carcinoids is one of the aims of endoscopic screening of the colorectum.

**Competing interests:** None

### References

- 1 Modlin I, Oberg K, Chung D et al. Gastroenteropancreatic neuroendocrine tumours. *Lancet Oncol* 2008; 9: 61–72
- 2 Modlin I, Drozdov I, Gustafsson B et al. Rectal neuroendocrine tumors – diagnosis and treatment. In: Modlin I, Oberg K (eds). A century of advances in neuroendocrine tumor biology and treatment. Hannover: Felsenstein CCCP, 2007: 124–133
- 3 Kaminski M, Polkowski M, Regula J et al. Prevalence and endoscopic features of rectal neuroendocrine tumors (carcinoids) among 50148 participants of the Polish colorectal-cancer screening programme. *Gut* 2007; 56 (Suppl III): A310
- 4 Matsui K, Iwase T, Kitagawa M. Small, polypoid-appearing carcinoid tumors of the rectum: clinicopathologic study of 16 cases and effectiveness of endoscopic treatment. *Am J Gastroenterol* 1993; 88: 1949–1953
- 5 Scherübl H. Options for gastroenteropancreatic neuroendocrine tumours. *Lancet Oncol* 2008; 9: 203
- 6 Soga J. Early-stage carcinoids of the gastrointestinal tract: an analysis of 1914 reported cases. *Cancer* 2005; 103: 1587–1595
- 7 Konishi T, Watanabe T, Kishimoto J et al. Prognosis and risk factors of metastasis in colorectal carcinoids: results of a nationwide registry over 15 years. *Gut* 2007; 56: 863–868
- 8 Konishi T, Watanabe T, Muto T et al. Risk factors for lymph node and distant metastasis in colorectal carcinoids: an analysis of nationwide registry in Japan over 15 years. *J Clin Oncol* 2006; 24: ASCO Abstract 3620
- 9 Konishi T, Watanabe T, Kishimoto J et al. Prognosis and metastatic potential of colorectal carcinoids compared with adenocarcinomas: results of a nationwide registry over 15 years. *J Clin Oncol* 2008; 26: ASCO Abstract 4054

- 10 *Sauven P, Ridge J, Quan S et al.* Anorectal carcinoid tumors. Is aggressive surgery warranted? *Ann Surg* 1990; 211: 67–71
- 11 *Tsukamoto S, Fujita S, Yamaguchi T et al.* Clinicopathological characteristics and prognosis of rectal well-differentiated neuroendocrine tumors. *Int J Colorectal Dis* 2008; 23: 1109–1113
- 12 *Modlin I, Lye K, Kidd M.* A 5-decade analysis of 13 715 carcinoid tumors. *Cancer* 2003; 97: 934–959
- 13 *Shim K, Yang S, Myung S et al.* Atypical endoscopic features of rectal carcinoids. *Endoscopy* 2004; 36: 313–316
- 14 *Wang A, Ahmad N.* Rectal carcinoids. *Curr Opin Gastroenterol* 2006; 22: 529–535
- 15 *Kim BN, Sohn DK, Hong CW et al.* Atypical endoscopic features can be associated with metastasis in rectal carcinoid tumors. *Surg Endosc* 2008; 22: 1992–1996
- 16 *Kwaan M, Goldberg J, Bleday R et al.* Rectal carcinoid tumors: review of results after endoscopic and surgical therapy. *Arch Surg* 2008; 143: 471–475
- 17 *Ramage J, Goretzki P, Manfredi R et al.* Consensus guidelines for the management of patients with digestive neuroendocrine tumours: well-differentiated colon and rectum tumour/carcinoma. *Neuroendocrinology* 2008; 87: 31–39
- 18 *Shinohara T, Hotta T, Oyama T.* Rectal carcinoid tumor, 6 mm in diameter, with lymph node metastases. *Endoscopy* 2008; 40 (Suppl 2): E40–E41
- 19 *Scherübl H, Bader M, Fett U et al.* Somatostatin-receptor imaging of neuroendocrine gastroenteropancreatic tumors. *Gastroenterology* 1993; 105: 1705–1709
- 20 *Sakata H, Iwakiri R, Ootani A et al.* A pilot randomised controlled study to evaluate endoscopic resection using a ligation device for rectal carcinoid tumors. *World J Gastroenterol* 2006; 12: 4026–4028
- 21 *Mashimo Y, Matsuda T, Uraoka T et al.* Endoscopic submucosal resection with a ligation device is an effective and safe treatment for carcinoid tumors in the lower rectum. *J Gastroenterol Hepatol* 2008; 23: 218–221
- 22 *Onozato Y, Kakizaki S, Ishihara H et al.* Endoscopic submucosal dissection for rectal tumors. *Endoscopy* 2007; 39: 423–427
- 23 *Kim YJ, Lee SK, Cheon JH et al.* Efficacy of endoscopic resection for small rectal carcinoid: a retrospective study. *Korean J Gastroenterol* 2008; 51: 174–180
- 24 *Kobayashi K, Katsumata T, Yoshizawa S et al.* Indications of endoscopic polypectomy for rectal carcinoid tumors and clinical usefulness of endoscopic ultrasonography. *Dis Colon Rectum* 2005; 48: 285–291
- 25 *Scherübl H.* Comment on Ramage et al.: Consensus guidelines for the management of patients with digestive neuroendocrine tumours: well-differentiated colon and rectum tumour/carcinoma. *Neuroendocrinology* 2008; 88: 157–159
- 26 *Höpfner M, Schuppan D, Scherübl H.* Treatment of gastrointestinal neuroendocrine tumors with inhibitors of growth factor receptors and their signaling pathways: recent advances and future perspectives. *World J Gastroenterol* 2008; 14: 2461–2473